

A STUDY ON ENTHESOPHYTE OF RADIAL TUBEROSITY AND ITS CLINICAL SIGNIFICANCE

G.E. Venugopal¹, M. Chelladurai², K. Vengadachalam³, J. Sujitha Jacinth⁴, J.K. Raja⁵

Received : 10/10/2025
 Received in revised form : 28/11/2025
 Accepted : 16/12/2025

Keywords:
 Radial Tuberosity, Enthesophyte.

Corresponding Author:
 Dr. G.E. Venugopal,
 Email: gevenugopal121@gmail.com

DOI: 10.47009/jamp.2025.7.6.168

Source of Support: Nil,
 Conflict of Interest: None declared

Int J Acad Med Pharm
 2025; 7 (6); 608-610



¹Associate Professor, Department of Anatomy, Govt. Thiruvannamalai Medical College, Thiruvannamalai, Tamil Nadu India.

²Associate Professor, Department of Anatomy, Nandha Medical College, Erode, India.

³Associate Professor, Department of Anatomy, Govt. Cuddalore Medical College, Chidambaram, India.

⁴Associate Professor, Department of Anatomy, Govt. Cuddalore Medical College, Chidambaram.

⁵Professor, Department of Anatomy, Govt. Thiruvannamalai Medical College, Thiruvannamalai, Tamil Nadu India.

ABSTRACT

Background: The radius is the lateral bone of the forearm and it lies parallel to ulna. Radius has upper end, lower end and an intervening shaft. The upper end of radius has head, neck and radial tuberosity. The radial tuberosity lies below medial side of neck and has a rough posterior part and a smooth anterior part. Tendon of biceps brachii gets inserted into the rough part of radial tuberosity. Sometimes a bony prominence occurs on the radial tuberosity due to overuse of the biceps brachii tendon. This bony prominence is called enthesophyte. The aim of this study is to study the occurrence of enthesophyte on radial tuberosity. **Materials and Methods:** 100 dry adult human radii (Right- 48, Left - 52) collected from the Department of Anatomy, Government Cuddalore Medical College, Chidambaram and Govt. Thiruvannamalai Medical College, Thiruvannamalai were studied for the presence of enthesophyte. **Result:** Out of the hundred radii studied enthesophytes were found in six (6%), of which four occurred on right side (4%) and two on left side (2%). **Conclusion:** Knowledge regarding the presence of enthesophyte on the radial tuberosity will enable the clinicians to understand the cause of pain and restriction of movements of forearm.

INTRODUCTION

Radius is the lateral and preaxial bone of the forearm and it is homologous with the tibia of lower limb. Since it is a long bone it has expanded proximal and distal ends and an intervening shaft. Its proximal end includes a head, neck and tuberosity. The head is discoid. Its proximal surface is a shallow cup which articulates with the humeral capitulum. Its smooth articular periphery is vertically deepest medially, where it contacts the ulnar radial notch. The neck is the constriction distal to head, which overhangs it, especially on the lateral side. It is enclosed by the annular ligament. The radial tuberosity lies just below the medial part of the neck. It has a rough posterior part and a smooth anterior part. The rough posterior part receives the insertion of tendon of biceps brachii muscle. The anterior smooth part is separated from the posterior part by a bursa.^[1] Enthesophytes are bony projections at the attachment of a tendon or ligament. The functions of this are to anchor tendon or ligament, dissipation of stress and acts as mini growth plates. In the radius they commonly appear on the posterior part of radial

tuberosity. They also appear on the feet and hand bones. In some cases, this bony projection is seen in entire skeletal structures. The clinical significance of this enthesophytes is that they may damage the surrounding structures, causes tendinitis and muscle spasm thereby leading to restriction of movements. This study is carried out to observe the presence of the enthesophyte in radial tuberosity at the upper end of radius as it is clinically significant.

MATERIALS AND METHODS

The study was conducted using 100 dry human radii (48 right, 52 left), collected from the Department of Anatomy, Government Cuddalore Medical College, Chidambaram. and Govt. Thiruvannamalai Medical College, Thiruvannamalai. The side of the radius was first determined and then inspected for the occurrence of enthesophyte on the posterior part of the radial tuberosity. The results obtained were tabulated in table no:1.

RESULTS

On observation enthesophytes were seen on the posterior aspect of the radial tuberosity in six (6%) bones. Out of this, four are seen in right side (4%) (Fig: 1 & 2) and two in left side (2%) (Fig: 3).

Table 1: Occurrence of Enthesophyte in Radius bone

No. of Radius bone studied		No. of Radius bone with Enthesophyte	Percentage of Occurrence
Right side Radius	48	4	4%
Left side Radius	52	2	2%
Total	100	6	6%




Figure 1: Right Radius bone showing enthesophyte



Figure 3: Left Radius bone showing enthesophyte

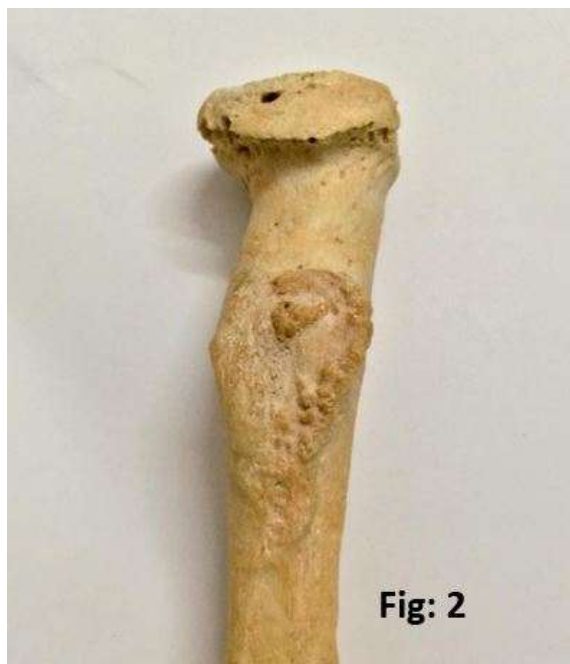

Figure 2: Right Radius bone showing enthesophyte

DISCUSSION

Osteophytes and enthesophyte formation are most commonly observed in adult bones. Osteophytes are lateral outgrowths of bone seen at the joint margin of the articular surface of synovial joints.

Enthesis is defined as the site in a bone where tendon, ligament, fascia or articular capsule is inserted.^[2] These are due to stress related skeletal responses. Endochondral ossification produces both osteophytes and enthesophytes. Mechanical stimuli seem to be next factor. Studies proved that osteocyte formation is due to altered joint mechanics and enthesophytes are formed along the direction of pull of tendon or ligament.

Enthesophytes may be developed as a result of repetitive strain. This correlates with the mechanical stimuli to be a factor for the formation of enthesophytes. Entheses are classified according to its structure and location. It may be osteotendinous or osteoligamentous. Depending upon on its structure it is classified as fibrous where periosteum is present and fibrocartilaginous where periosteum is absent. Based on location it is of chondro-apophyseal and periosteal-diaphyseal types.^[3] Enthesis organ are

collection of physiologically uniform tissues which are close to entheses and helps in dissipation of stress at the surface of bones. Enthesopathies are defined as any abnormal change in the entheses mainly due to overusage of related muscles. Clinical conditions associated with enthesopathies are spondyloarthropathy, rheumatoid arthritis, diffuse idiopathic skeletal hyperostosis and calcium pyrophosphate deposit diseases.^[4] Theories proposed for the pathogenesis of enthesophytes are inflammatory theory, molecular theory and mechanical theory. According to inflammatory theory TGF-Beta and BMPs induce the enthesophyte formation. Molecular theory suggested that the mesenchymal stem cells act as progenitor for formation of enthesophytes. Mechanical theory proposed that any irritation produce damages to the periosteum which in turn stimulates the differentiation of osteoblasts into enthesophytes.^[5] Histological features of this enthesis organ are that they are multilayered with four zones of tissues namely pure dense fibrous connective tissue, noncalcified fibrocartilage, calcified fibrocartilage and bone respectively.^[6]

The incidence of enthesophytes in literature is approximately 3% (three cases) which were found projecting from the posterior aspect of the radial tuberosity. In our study the occurrence of enthesophyte is 6%.

Enthesophyte formation is more in male and this may be due to increased skeletal muscle mass thereby leading to increased bone forming phenotype. Enthesophytes proportionally increases with age in addition to environmental and hormonal factors.

In our study it is more seen in right side bones as right hand is used more for work leading to chronic strain than left hand. A positive correlation was noticed between the occurrence of osteophyte and enthesophyte where the joint mechanics gets altered in chronic strain.^[7]

The following may be considered for the mechanism of formation of enthesophytes in radial tuberosity. Tendon of biceps brachii is inserted into the radial tuberosity. This muscle causes supination of forearm in flexed elbow thereby screwing movement of this muscle fibers are produced. when this is overstrained there is possibility of microtrauma in tendon, which later gets ossified and exostosis is formed. The periosteum of this bony part may get elevated due to overstretching of this muscle osteocytes in the osteogenic layer of bone gets exposed leading to further bone formation. Inflammation of the entheses in seronegative spondyloarthropathies leads to enthesophyte formation. multiple idiopathic enthesophytes in radius are commonly seen in diffuse idiopathic skeletal hyperostosis. calcium metabolic disorders lead to calcium deposition in tendon of

biceps and gets ossified. remodelling process during enchondral ossification of radius may be improper.^[8] Clinical implications of this enthesophytes are mostly compression of neighbouring structures, it can impinge on the tendon of biceps leading to tendinitis. It can damage the radial artery. Pain and restriction of movements of forearm can be expected as clinical feature. Radiologically enthesophytes can be visualized in the living. The presence of enthesophytes may mislead the radiologist for interpretation and for orthopaedicians to manage the treatment of fracture of radius.^[9]

Enthesophytes also appear on the feet, either along toes or the heels, as well as on the hands. In extreme cases bony spurs have grown along a person's entire skeletal structure— along the knees, hips, shoulders, ribs, arms and ankles. Such cases are only exhibited with multiple exostoses. Bony exostoses are common around the shoulder, hand and feet. They have also been reported on the posterior aspect of the superior surface of the olecranon process of ulna, projecting in obturator foramen, arising from external occipital protuberance and arising from iliac crest.

CONCLUSION

This study provides a knowledge and occurrence of enthesophytes in radius which will be helpful for anatomists, radiologist to avoid misinterpretation and orthopaedicians for effective treatment.

REFERENCES

1. Standring S: Gray's Anatomy: The Anatomical Basis of the Clinical Practice, 39th edition. Edinburgh; Elsevier Churchill Livingstone. 2006; 869-870.
2. Rogers J, Shepstone L, Dieppe P. Bone formers: osteophyte and enthesophyte formation are positively associated. *Ann Rheum Dis* 1997; 56: 85-90.
3. Benjamin M, Toumi H, Ralphs JR, Bydder G, Best TM, Milz S. Where tendons and ligaments meet bone: attachment sites ('entheses') in relation to exercise and/or mechanical load. *J. Anat.* 2006; 208: 471-90.
4. Slobodin G, Rozenbaum M, Boulman N, Rosner I. Varied presentations of enthesopathy. *Sermin Arthritis Rheum* .2007; 37: 119-26.
5. Sudol-Szopinska I, Kwiatkowska B, Prochorec Sobieszek M, Maslinski W. Enthesopathies and enthesitis part 1 etiopathogenesis. *J Ultrason* .2015; 15(60): 72-84.
6. Francois RJ, Braun J, Khan MA: Entheses and enthesitis: A histopathological review and relevance to spondyloarthritides. *Curr Opin Rheumatol* . 2001; 13: 255-264.
7. Gibson N, Guermazi A, Clancy M, Niju J, Grayson P, Aliabadi P et al. Relation of hand enthesophytes with knee enthesopathy: Is osteoarthritis related to a systemic enthesopathy? *J Rheumatol* 2012; 39: 359-64.
8. Singh R. Enthesophyte on the radius : a case report. *OA Case Reports* 2013 June 21; 2(5): 47.
9. Resnick D, Niwayama G. Entheses and enthesopathy: anatomical, pathological and radiological correlation. *Radiology* 1983; 146: 1-9.
10. Benjamin M, Ralphs JR. The cell and development biology of tendons and ligaments. *Int Rev Cytol* 2000; 196: 85-130.